

WEST AFRICAN
LYMPHATIC FILARIASIS MORBIDITY PROJECT

SURGICAL HANDBOOK

An Aid to District Hospital Surgeons

2nd edition, Summer 2007

Sunny D. Mante
Anders R. Seim



LF -Filaricele surgery handbook*

IMPORTANT NOTICE: Techniques described in this Handbook are only for treating LF patients who have normal scrotal skin! ~~together with their LF-hydrocele/filaricele.~~

~~The~~ **s** Surgical techniques described here and during The West Africa LF-Morbidity Project's training workshops are contraindicated in patients with significant lymphoedema of the scrotal skin, elephantiasis of the scrotum, or lymph-scrotum. Such ~~other~~ conditions may generally require reconstructive surgery.

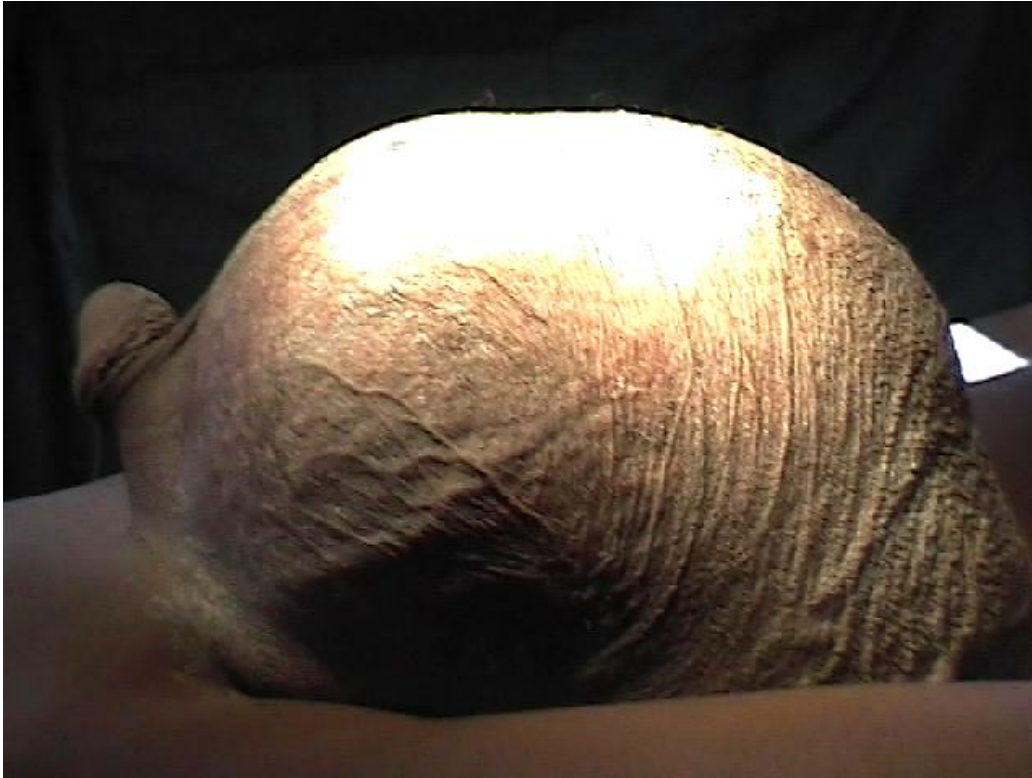In ~~those~~ such cases, both procedures (filaricele resection and reconstructive urogenital surgery) should be done in a single session and using a different surgical technique on the LF-hydrocele sac.

Reconstructive LF-surgery must always be undertaken at tertiary-care hospitals by expert surgeons who have extensive experience in skin transplants and the highly specialized care of such LF-related conditions.

Techniques described here are only for use on "ordinary" cases of LF-hydrocele/filaricele that are uncomplicated by skin manifestations.

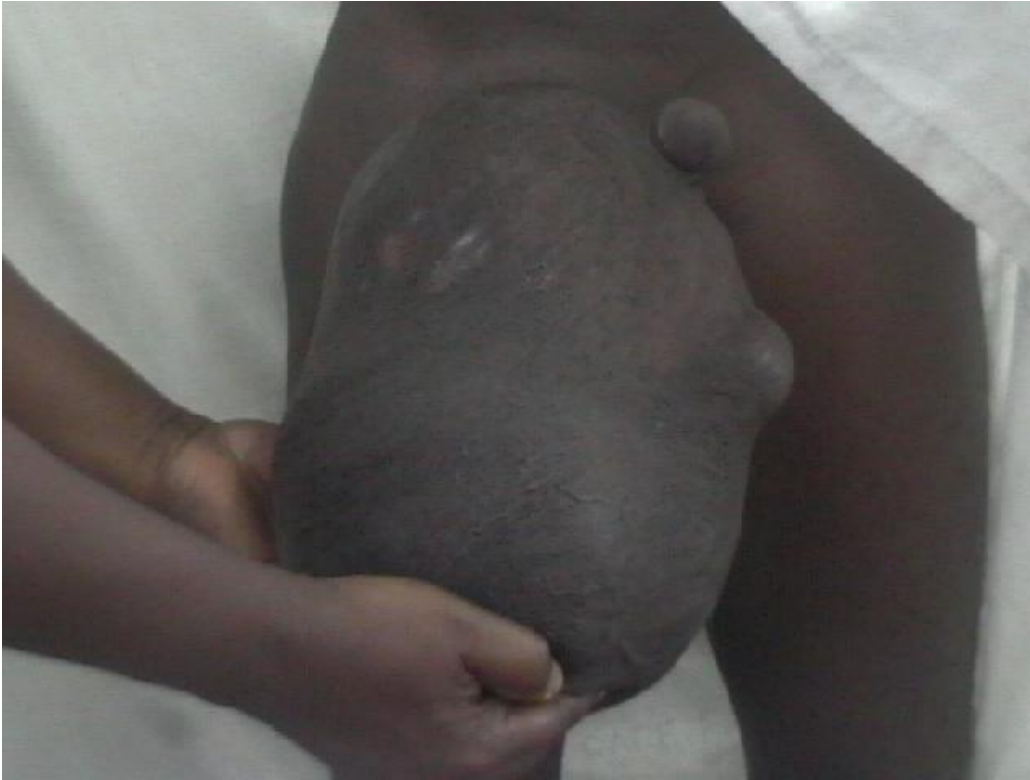Note for the 2nd edition: The technique taught here has been well received by colleagues working in district hospitals in Africa. This 2nd edition has been updated and modifications introduced based on three years of experience teaching LF-hydrocele surgery and outcomes evaluations that showed some clarifications to be necessary.

* Presentation of information in this handbook does not constitute "publication". Information is presented here as an aid to memory especially for surgeons participating in educational LF-surgery workshops under the West African LF-Morbidity Project. This is not intended as a definitive text. A more in-depth text is being prepared for publication by Prof. J. Noroes of Recife, Brazil, who has contributed massively to the preparation of this handbook through his years of research and clinical work on LF, as well as to wording in the Handbook itself. Any mistakes are nevertheless the fault of the authors. Material in this booklet may be reproduced, extracted, or copied in part or in whole, for educational, purely non-commercial purposes pertaining to national LF Elimination activities, and on the condition that the authors are recognized. Rights are retained by the authors.



LF-hydrocele / filaricel, a debilitating, impoverishing condition that afflicts an estimated 40 million men in 83 countries.

This 50 year old incapacitated farmer with 5 children had his filaricel for 20 years. It contained 4.2 liters of fluid, making farm work and procurement of income for his family all but impossible.



A 35 year old man whose scrotum contained approximately 2 litres of fluid, significantly hampering him in his work as a farmer. His wife had left him because of his condition.

Table of Contents

	Page
A. Pre-operative requirements	
Patient overview and medical / surgical history form	5
Pre-op. laboratory investigations	7
Transillumination to light	8
Ultrasonography of the scrotum	9
Informed consent form	12
B. Other pre-operative necessities	13
C. Intra-operative requirements and procedures	14
D. Post operative care	25
E. External evaluations	27
Literature	28
Annexes	
1. Pathogenesis	29
2. Local anesthesia for LF-hydrocele / filaricele	30
3. Relevant anatomical highlights	31
4. Patient care and follow-up form	33
5. Data collection form-socioeconomic impact; surgery outcomes	36
6. Recipe for permanganate solution	38
7. Equipment list – Instruments and Disposables for LF surgery	39
Acknowledgements	41

Comments:

9.2. Blood pressure:

9.3. State of conjunctiva:

NOTE: This is mainly to assure against operating on a jaundiced patient, e.g. in situations where routine pre-operative liver-function tests may not be available. It will also give warning of potentially severely depressed haemoglobin (Hgb) level / severe anemia. Hgb should in all cases be measured pre-operatively.

9.4. SCROTAL EXAMINATION

9.4.1. Inspection of the skin

Look for skin infection and entry lesions of all kinds, lymphoedema, lymph-scrotum, warts etc.

NOTE: It is very important to rule out any infection of the skin, even if it is outside of the genital area. Urethritis should also be ruled out or treated prior to any urogenital surgery.

9.4.2. Palpation findings

Determine whether the swelling is purely scrotal or inguino-scrotal. You are trying to determine whether the swelling is a filaricele, a hernia, or a filaricele and a hernia in the same patient.

NOTE: The point is that the surgery is different, with the incision placed very differently, if hernia is involved.

9.4.3. Transillumination / Ultrasound findings

(see p. 8-11 regarding transillumination and ultrasound)

9.5. Status of the penis

Detect any lymphoedema and/or urethral secretion, or other skin lesions

Note: Urethritis and any infected skin lesion should be treated prior to any urogenital surgery.

9.6. Examine the limbs

Verify the presence or absence of any lymphoedema, entry lesion(s), and/or skin infection.

10. Pre-operative Laboratory Investigations

10.1 Haemoglobin:

10.2. Filariasis blood tests:

10.2.1 Thick blood film for microfilaria:

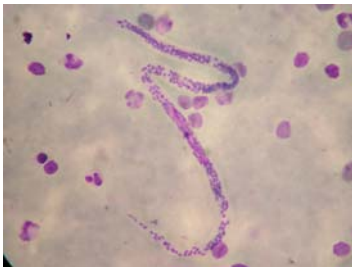

Photo 1.

Photo 1. Microfilaria in thick blood film stained with Geimsa; x400 lens.

10.2.2. Antigen Card Test result (if done):

10.3. Simple urinalysis for protein, sugar, red blood cells, etc.
Urinalysis Results:

10.4. If urine-sugar positive, one should measure serum blood-sugar.
Blood sugar result:

NOTE: Deal with any diabetes before considering operation for LF-hydrocele/filaricelce. Only patients with stable, normal or essentially normal blood sugar should be considered for scrotal surgery because of the elevated risk of post-operative infection that comes with inadequately controlled diabetes.

10.5. Results of any other blood tests done:

(End of patient registration form, p. 5 - 7)

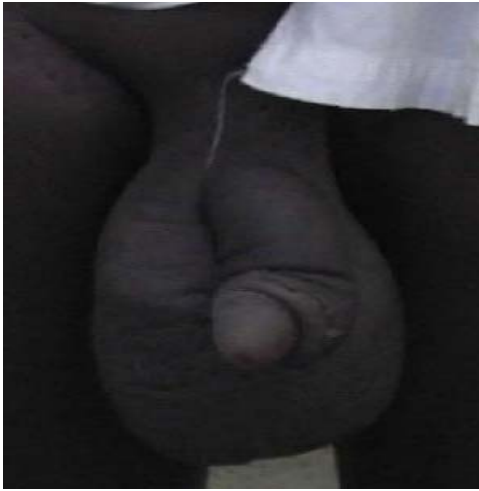

Photo 2. Lymphoedematous penis and scrotum where operation is contraindicated at normal district and regional hospitals.

Transillumination to light

NOTE: Transillumination is non-specific and not considered an adequate tool for pre-operatively assessing cases believed to be LF-hydrocele. If positive, it means there is a thin sac wall and may indicate fairly clear fluid in the sac, but it reveals nothing about the origin of that fluid. Where ultrasound is available, transillumination is not necessary, as it offers no additional information.

Where possible, the patient should always be examined using ultrasound to differentiate between congenital hydrocele on the one hand, and LF-associated conditions with lymphangectasia on the other hand, detect possible worm-nests and determine their location, etc. Also, ultrasound permits proper pre-operative assessment of the testis, etc, which is important.

Transillumination is mentioned here, only because some consider that it provides a little useful information in hospitals that do not have access to ultrasound examination.

NOTE: If transillumination is negative, it means one may be facing a complex situation (including possible tumor, chylocele, etc). Negative transillumination occurs quite frequently even in LF-hydrocele, in cases where the sac wall is thick, and in some cases where the fluid contains significant amounts of blood or other cellular matter; in some cases where the lymph fluid in the filaricel has had access to the testis and led to testicular necrosis with testicular matter mixed in with the fluid, etc. Differentiation from tumor is often possible based on palpation and other clinical findings. Careful palpation is more reliable than transillumination for differentiating from tumor. Cases with negative transillumination can be operated on in district hospitals if the surgeon is prepared to deal with situations that may not be typical filaricel. In cases where transillumination is negative, you may consider referring the patient to a secondary hospital, depending on your hospital's surgical equipment and your own level of experience as a surgeon.



Photo 3. Transillumination test positive, much more obviously so than is usual.

Ultrasonography of the scrotum

NOTE: Where available, ultrasonography at 7.5 mHz is considered important for differentiating conditions like epididymal cyst, varicocele, and testicular tumour. It also helps you know the state of the testis before surgery, whether it's atrophic or not. Accuracy of ultrasound examination is examiner-dependent, and the tool is generally not yet available in some West African district hospitals.

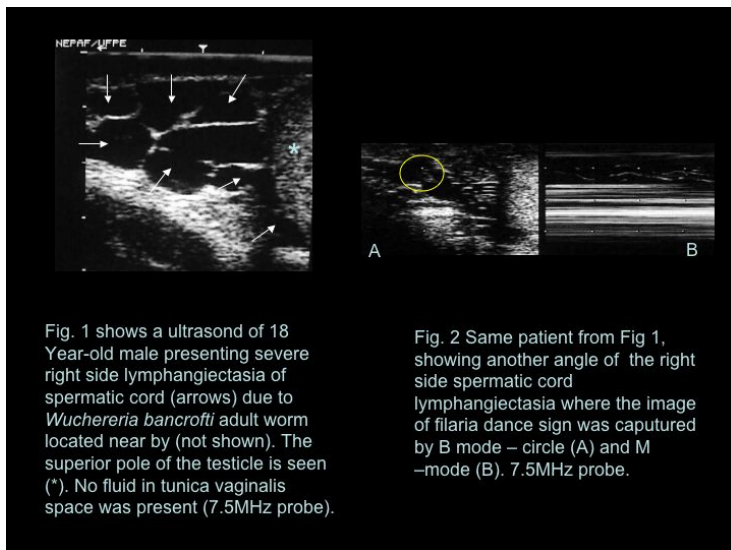


Fig. 1 shows a ultrasound of 18 Year-old male presenting severe right side lymphangiectasia of spermatic cord (arrows) due to *Wuchereria bancrofti* adult worm located near by (not shown). The superior pole of the testicle is seen (*). No fluid in tunica vaginalis space was present (7.5MHz probe).

Fig. 2 Same patient from Fig 1, showing another angle of the right side spermatic cord lymphangiectasia where the image of filaria dance sign was captured by B mode – circle (A) and M –mode (B). 7.5MHz probe.

Photo 4. Lymphangiectasia along the spermatic cord

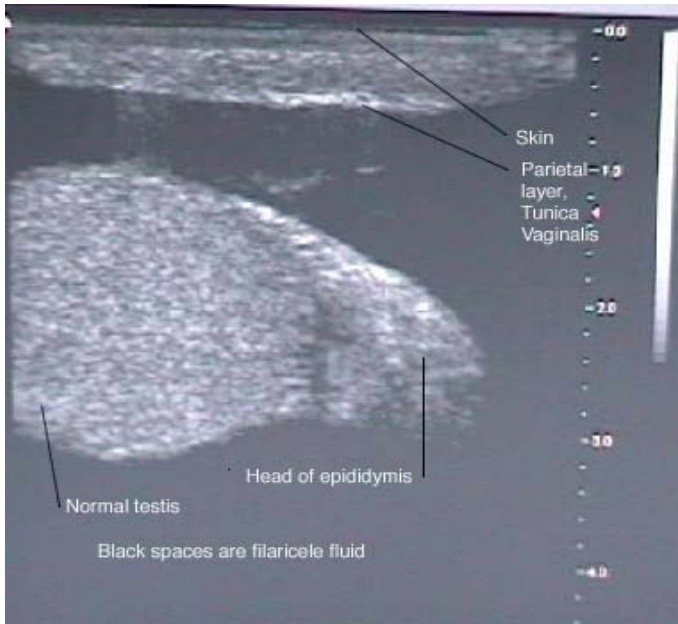


Photo 5. Typical LF-hydrocele/filaricele, black, anechoic fluid around a normal testicle (transillumination positive). Epididymis to the right and above the testis.

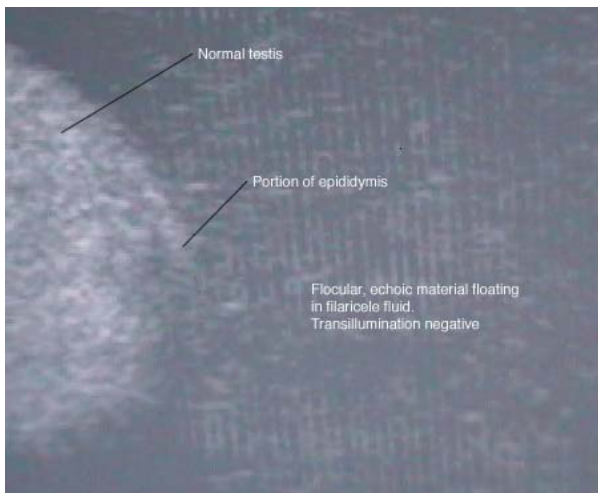


Photo 6. Filaricele/LF-hydrocele with flocular, richly echoic particles in the fluid (transillumination negative).

Examination of the limbs for signs of oedema, entry lesions, and/or skin infection.

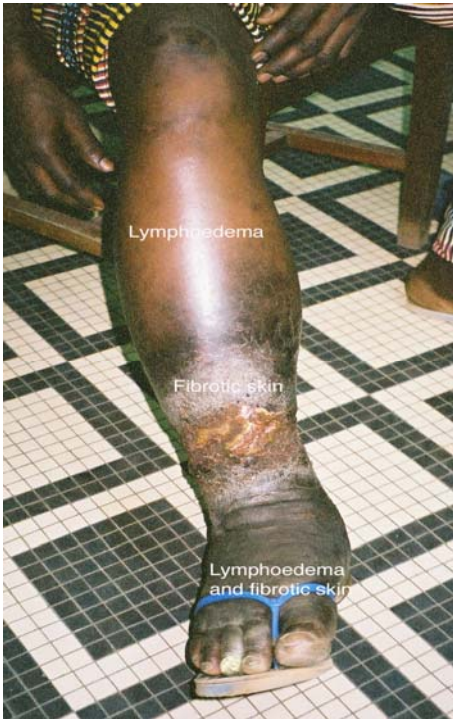

Photo 7 . Limb oedema with fibrotic skin. The appearance here is consistent with venous insufficiency.

Informed Consent

I consent to undergo the operation of filaricelle surgery, the consequences of which have been explained to me.

This operation will be done under anaesthesia, and I will be on admission for one week~~not less than one day~~, after which I will be discharged and I will be coming for dressings until my wound heals completely. Possible complications that sometimes occur after surgery even though the surgeon will do what (s)he can to avoid them include one or more of the following: bleeding (haemorrhage), blood collection in the scrotum (haematoma), infection (fever etc), return of the problem, etc.

I have been explained that I must take 2 types of anti-infection tablets (antibiotics), three times **each** day for at least 5 days after the operation.

I have been explained and I understand that it is very important to take the tablets exactly in the way I have been instructed, for the entire 5-7 day period of the treatment. I understand that taking these tablets in the right way is very important for a good result of the surgery. I have also been explained that I will be given tablets to take against any pain after the operation, and I have been explained how to take those tablets.

I also agree that photos or clinical data about my condition, its treatment and the results may be used in research and scientific publications.

Signed

Witness

Date /Day

B. Other pre operative necessities

1. **Good bath** with thorough washing of the genital area but also the whole body using soap and water, both the day before surgery and on the morning of surgery.

2. **Close-cutting or shaving of scrotal hair**

The day before the operation, after the head-to-toe washing, the patient should be provided a good scissors and instructed that he is to carefully cut all genital hair, especially that on the scrotum but also the rest of his pubic hair. He is to cut hairs very close to the skin, being careful not to damage the skin itself.

In many localities, carefully shaving the skin is seen as the only acceptable pre-operative method for hair removal. Shaving should be done with extreme care to avoid damaging ~~the~~ scrotal skin. Skin damage makes infection more likely.

NOTE: In some centres it is considered important not to shave the skin as they see evidence that post-operative infections are perhaps more common after shaving, as a result of small nicks and cuts of the skin during the shaving process. The evening before surgery, staff needs to confirm a proper result has been obtained by the patient, and that all public hair has been cut very short, especially on the scrotum.

3. **Pre-operative antibiotic dose**^{**}

The initial dose of both antibiotics (see the first item of Post-Operative Care, below) must be ~~given started~~ the evening day before surgery and a dose of both antibiotics given on the morning of surgery. In our setting it is considered very important for the patient to be under proper antibiotic coverage during the operation itself. Depending on the type of anesthesia chosen, the patient may need to be fasting or on only small amounts of liquids during the day of surgery, ~~so it is considered important that the initial antibiotic dose be given the previous evening~~ Experience in rural African settings shows very clearly that hydrocele surgery of all types needs to be done under a proper antibiotic umbrella. Otherwise you risk an unacceptably high rate of post-operative infections, and even disastrous outcomes.

^{**} Because of the high risk of post-operative infections in settings where this handbook will be used in Western Africa, and the often disastrous consequences of such infections when they occur in and around the genitalia, the Project Urologist suggests that surgeons working in peripheral African hospitals should ~~consider definitely use ing~~ pre- and post-operative systemic antibiotic medication as specified below. ~~An indication of p~~ The fact that post-operative infections have been seen in in 25%-30% of cases following traditional filaricele surgery in African countries, regardless of surgical methodology, in an African country, can be seen as supports for the this Project's recommendation to use pre- and post-operative antibiotics for filaricele surgery in this our setting. In ~~most some~~ other settings, ~~even in many developing countries (including some major African medical centres)~~, antibiotic cover would not be recommended for filaricele surgery because it would be adequate to treat only the very few patients who experience post-operative infections in those other settings. In general, it is best for the population and the individual patient that doctors avoid using antibiotics except when really needed.

4. Morning Temperature on day of surgery

Consider postponing surgery if the patient's temperature on the morning of surgery is >37.5 degrees Centigrade. If so, also take a blood sample for malaria microscopy and other measures to diagnose and treat any infection, so surgery may become possible as soon as possible.

C. Intra-operative Requirements and Procedures

PLEASE SEE IMPORTANT NOTE INSIDE THE FRONT COVER!

1. Anaesthesia

1.1. Pre-Operative Medication

- a. Diazepam 10 mg i.v. just before surgery ~~p.o. approx. 2 hours pre-op.~~

AND

- b. ~~Pethidine 50 mg. i.m.~~ e.g. when the surgeon starts scrubbing, keeping the remaining 50 mg. available for the not so rare cases where more is needed. (Pethidine may not be available in some countries. Tramadol 50 mg. can then be injected as an anti-inflammatory analgesic.)

1.2. Per-Operative Anaesthesia

Local, spinal, or (rarely in Africa) general anaesthesia

Local anaesthesia will be the norm in many hospitals in our settings. (Please see Annex 2 for more details.) Spinal or general anaesthesia may be preferred when one has an anaesthetist available with the skill and equipment to do it.

Local anaesthesia (Xylocain with adrenaline) is placed as follows:

- a) ~~10~~ 5 ml. in and just on the ventral aspect of ~~the-both~~ spermatic cords near the external ring of the inguinal canal; b) along the median raphae; c) infiltrated well on both sides of the median raphae.

NOTE: Where available, bupivacaine (in a 1:1 dilution with normal saline or water ad inj.) gives a strong and longer lasting effect, and thus requires less drug for the same local anaesthesia time. It may therefore also be less costly all told. However, in most of our settings, bupivacaine may not be available.

As always, patients with a large alcohol consumption may need and tolerate different doses, sometimes be hyper-reactive, need to be given special attention as concerns fluid and sometimes sugar intake, etc.

Total xylocain usage is typically 50 – 70 ml. Maximum total dose: < 400 mg.

Somebody should be sitting at the head of the patient throughout the procedure, not least under local anaesthesia, to register the patient's condition and to react promptly if facial contraction or other signs indicate that additional, top-up anaesthetic needs to be injected in and in front of the cord. The patient and the surgeon both benefit if the patient is free of pain.

When top-up xylocain is given, you should give at least 5 ml at a time. 10 ml. is usually better.

Also, consider topping up the pethidine dose. Many patients, especially young men, need and tolerate a topping up of their pethidine dose with an additional 25-50 mg, to a total dose of 75-100mg.

Alcoholics and persons with considerable alcohol consumption need special care. They can become agitated at surgery and hypoglycaemic. The liver of such persons may not easily release glucose under stress. Therefore, access to a dextrose drip or sugar cubes and a bit of water in the form of soaked compresses that the patient can suck on is important in such cases.

2. **2.**—**Thorough cleaning** of the genital area with soap (e.g. ordinary liquid dish-washing soap) and water is undertaken on the operating table. This is done in addition to the patient's shower the previous evening, before the thorough pre-operative skin-disinfection of the genital area by the surgeon.

Formatted: Bullets and Numbering

The pre-operative day and on the morning of surgery, as well as on the operating table, be sure to clean under the preputium in uncircumcised men!

3. **Midline incision**

The incision is along the median raphe of the scrotum, beginning about 2cm (about two finger-widths) below the base of the penis and extending for a distance of typically 5-7cm, depending on the size of the filaricele.

4. **Total, gentle dissection** of the filaricele. As part of the dissection, the filaricele is pressed out through the surgical incision, being careful to avoid rupture if possible.

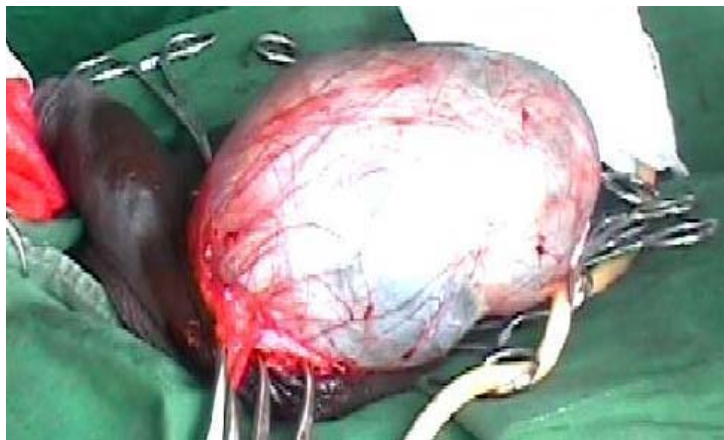


Photo 8. Successfully exposed filaricele

NOTE: When the filaricele is truly huge and heavy, the spermatic cord will often be highly stretched. Dissection must be done very carefully in such cases. In one documented case, the spermatic cord broke and the LF-hydrocele fell off the operating table onto the floor, previously viable testicle and all, when a careless surgeon allowed a huge LF-hydrocele to slip.

5. **Very Meticulous Hemostasis** of any bleeding from the edges of the skin and the inner surface of the scrotal wall and the outer surface of the filaricele sac is very important at

this point in the procedure, before proceeding to the next step.

- 5.1. Gauzes or compresses should be left in the hemi-scrotum cavity to minimize bleeding by compression and to give us an idea about the extent of any bleeding. This maneuver will help us to review the hemostasis at the end of the procedure.

NOTE: A cautery machine will be of great help during the haemostasis. You should seriously consider refraining from filaricele surgery if you do not have access to cautery, because the number of small bleeders can sometimes and unpredictably, though by no means always, be considerable and otherwise require a significant number of ties.

NOTE: You should repeatedly return to haemostasis on all structures dealt with during previous steps in the procedure. Soaked compresses should be replaced frequently, and used as an indicator of whether and where there may be ongoing bleeding. And any such bleeding should be taken care of. Many small veins may not bleed immediately, while structures are lifted from the surface and tissues are handled during the procedure. The small veins may only start oozing when the spermatic cord and testis are left lying still for a few minutes.

6. **Aspirate the filaricele fluid** with a large syringe or a suction device, and note the nature and amount (ml.) of fluid aspirated.

7. **Open the filaricele sac; inspect the testis;** note any abnormalities.
Between two clamps a midline incision is made beginning in the anterior and superior surface of the filaricele sac fairly near the tail of the epididymis and extended cephalically until the limit of the spermatic cord.

Now it is possible to inspect the whole interior part of the filaricele sac, the testicle, and the epididymis.

NOTE: In cases being treated for recurrence after a previous intervention that included eversion of the tunica vaginalis, one must at this point dissect the filaricele sac, separating it from the cord and other structures around which it will usually be wrapped, being careful not to damage the vas deferens and vessels in the spermatic cord. When the filaricele sac has been liberated from other structures, it is resected as in other cases.

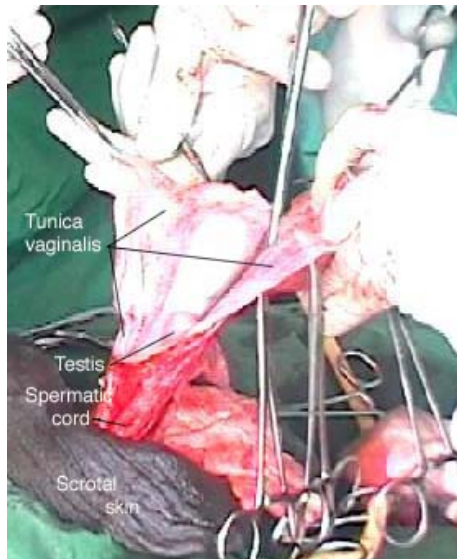

Photo 9. Filaricelc sac wall has been opened on the ventral side, exposing the testis and the epididymis. Both sides of the filaricelc sac are clamped. Next, the lateral side will be resected elose 1-2 cm from to the epididymis, and the median side will be excised elose 1-2 cm from to the testis.

NOTE: If there is a peritesticular cyst, be sure to look for and ligate the small stalk of blood vessels that is normally to be found in the cavity in which the cyst was located.

NOTE: If the filaricelc has been very large, the vas deferens will often have been thinly stretched and may have an unusual location in the filaricelc wall, making it difficult to recognize. Special care is therefore necessary in these cases, to avoid damaging the vas deferens during the dissection process.

NOTE: If the testis is seen to be obviously necrotic (Photo 10), the rest of the operation is simple in that you clamp the chord and perform a traditional orchietomy.

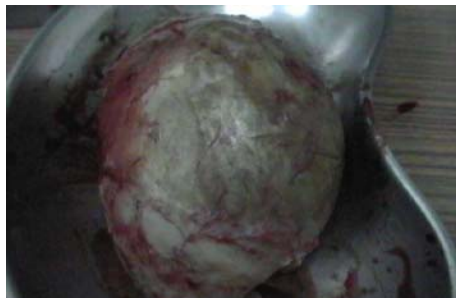

Photo 10. Necrotic testis in a thick, fibrotic filaricelc sac wall. (See Note above, under Step 7.)

8. Resecting the filaricele sac

Leaving approximately 1 ~~– 2.4.5.~~ cm. at the edge of the testis, and being especially careful at the epididymis and the vas deferens, carefully resect the filaricele sac. Check front and back several times, making sure the direction of the scissors is appropriate, to avoid damage, and see that a suitable border is left unresected.

In long-standing cases or with chylocele, the filaricele sac may be thickened and fibrosed, and in extreme cases calcified, making transillumination negative and resection of the filaricele sac difficult.

Especially in patients with very large filariceles, the distance between the epididymis and the testis may be increased. Leave the sac alone in this area! Do not resect any such additional tissue.

NOTE: If you ignore the advice to leave sac tissue located between the testis and the epididymis alone, you will have all kinds of problems, and the bleeding is terrible!!

NOTE: Again, special care must be taken here, in order not to damage the vas deferens which may be thin and difficult to recognize in cases where the filaricele was huge and the cord was heavily stretched.

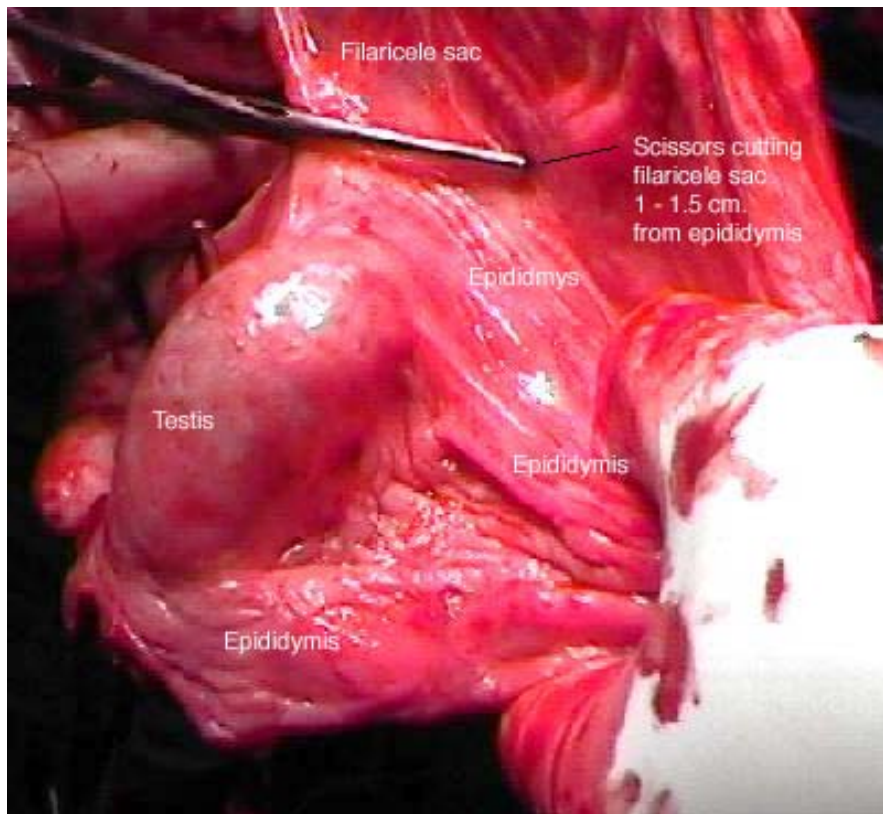


Photo 11. Resection of the filaricelae sac around the testis

9. Haemostasis of the remaining filaricelae sac edge

Use continuous interlocking ~~4-0 chromic catgut~~ 3-0 Vicryl sutures about 1 cm. apart quite close together at the cut edges of the tunica around the testis. ~~Some authors prefer cautery for this haemostasis.~~

~~NOTE: 4-0 sutures may not be available in all of our district hospitals. If that is the case, feel free to use 3-0 or even 2-0 chromic catgut or Vicryl. The same is true everywhere in this handbook where 4-0 suture or ties are recommended.~~

IMPORTANT NOTE: Vicryl knots tend to unravel! Therefore you must use 6 knots everywhere that you use Vicryl, and you must leave 1 – 1.5 cm. of thread above the knot when cutting the thread.

If you ignore this advice, you run a high risk of having your beautiful surgery ruined by bleeding and other problems that result from sutures coming untied.

NOTE Regarding Suture Material: Vicryl is generally preferable to chromic catgut because Vicryl gives less local reactive inflammation. Vicryl is now available in some-most or all of our Project's countries, ~~but not all. Vicryl can be used wherever this Handbook recommends the corresponding chromic catgut.~~

Special caution is needed to avoid suturing the epididymis in patients of reproductive age!

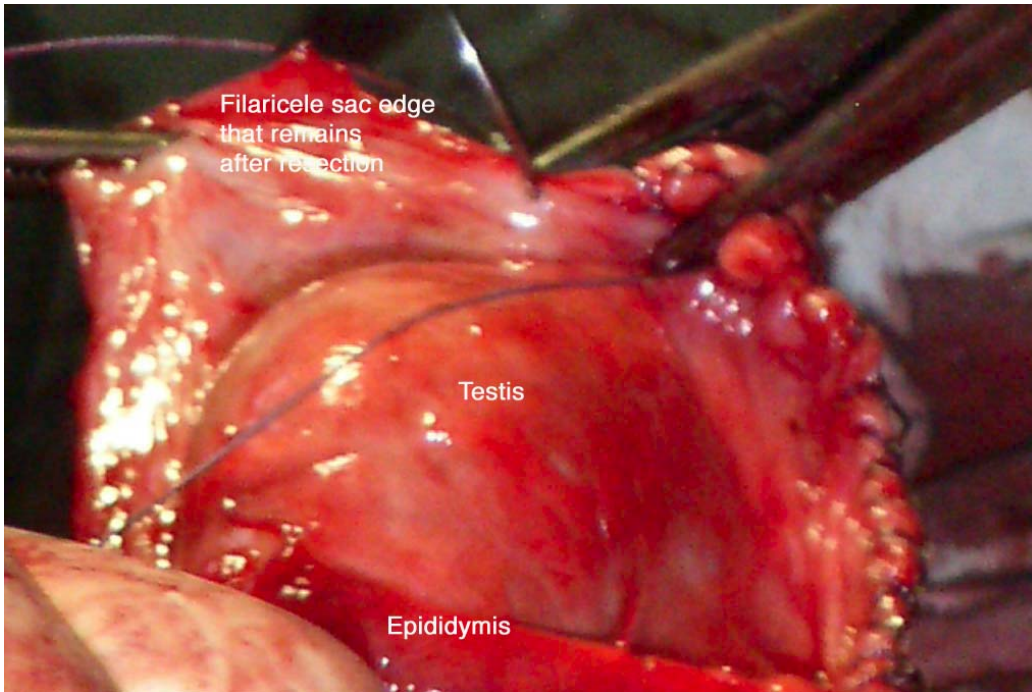


Photo 12. Interlocking sutures being placed along the filaricel sac's remaining edge

10. Haemostasis of the inner scrotal wall

When you think you are finished with Step 9, wrap the testis and cord in clean, [saline-soaked](#) compresses, and leave the testis lying on the field. Wait 5 minutes while you inspect the inner wall of the scrotum and deal with any bleeding there, as described in the paragraphs below. If there is no bleeding into the compress that has been wrapped around the testis and cord, you have good hemostasis and can put the testis in the scrotum, as described below in Step 11.

Having gently wrapped the testis in clean [gauze](#) and set it aside, prepare to take out the gauze placed in the hemi-scrotal cavity earlier.

The scrotal pouch is opened widely with clamps, avoiding the skin. The

compresses are removed, and the scrotal wall is inspected carefully.

Haemostasis is carefully and thoroughly secured on the inner wall of the scrotum with electrocautery if available, and otherwise using 3-0 Vicryl 4-0 chromic catgut ties.

11. Placing the testis and dealing with the excessive scrotal skin

This is a good moment to review the haemostasis AGAIN and confirm that there is no bleeding in the scrotal cavity, after you have unwrapped the testis and dealt with any bleeders that became evident while the testis was lying to the side since the end of Step 9.

Place the testis into the hemi-scrotal cavity. The testis should be placed at the bottom and distally in the scrotum.

NOTE: If you do not place the testis as described, the testicle will later come to be located very high in the scrotum and there will be a lot of skin inferiorly to it.

NOTE: Do not suture the testis to the scrotum. If you place the testis well at the bottom of the scrotum and bandage as suggested below, the fibrosis that forms will be enough to keep the testis nicely placed in the scrotum. If the testis is not placed carefully at the bottom, on the posterior wall and distally, it may end up being located high up towards the inguinal canal.

Be sure there is no torsion of the cord!

12. Do not resect scrotal skin !

Even with a large filaricele, the size of the scrotum will have normalized considerably even during the operation itself.

If you place the testis gently but firmly at the bottom of the scrotum as suggested in Step 11, the size of the scrotum will gradually become normal or close to normal later on.

If there was any undetected edema in the scrotal wall as a result of previous lymphatic filariasis damage to scrotal lymphatics and lymph capillaries, partial excision of the skin will not solve the problem, and you could worsen the situation if you resect scrotal skin.

Especially in our setting, in peripheral hospitals in Africa, but even elsewhere, it is generally **best not to excise any scrotal skin during LF-surgery.**

13. Closure of the scrotum

The scrotal wall should be closed in 2 layers.

The inner layer should be sutured using interrupted or running, continuous suturing with **remove the four** 4 3-0 chromic catgut (or Vicryl).

It is helpful to wash the area with Normal saline after closing of the inner layer and just prior to closing the skin.

The outer wall (the skin) is closed, using **4remove the four** 3-0 chromic catgut (or Vicryl), either as intracutaneous continuous suturing or interrupted sutures.

NOTE:

1. It is very important to achieve excellent approximation of the edges of the skin during surgical wound closure. There is a tendency for the edges of the skin to bulge between sutures if care is not taken. Gaps where subcutaneous tissue can be seen will delay wound healing by at least 2-3 weeks. This almost guarantees that you will have post-operative infection. Two – three minutes of care and attention to skin closure at the operating table prevents weeks of trouble afterward.

2. In cases where ~~there is evidence that~~ the patient's possibility for personal hygiene may be particularly bad, one may choose to close the scrotal skin using Nylon sutures if you are absolutely sure the patient will return to have the sutures removed. In the great majority of cases one can use Vicryl chromic catgut, making subsequent removal of sutures unnecessary. In some settings a tendency to post-operative seeping has been observed when chromic catgut was used in skin, and at these centres they prefer Nylon suture for skin. Others have not had problems with seeping after chromic catgut suturing of skin and are attracted by the advantages of self-resorbing skin sutures, especially in situations where patients may quickly be lost to follow-up. It is possible that there is less tendency to seeping after catgut suture when the incision is along the midline scrotal raphe rather than the lateral but caudo-cephalic incisions used elsewhere for unilateral filariceles. The authors are not aware of comparative studies on this detail, and the Project urologist has not seen problems with seepage after intracutaneous chromic catgut suturing of the skin along the midline raphe.

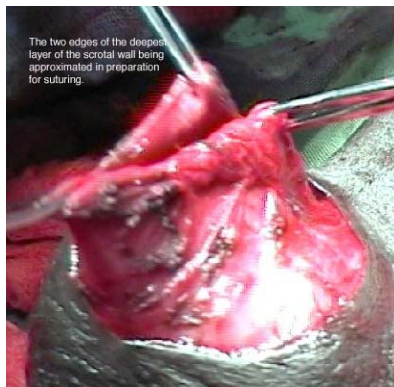

Photo 13 a

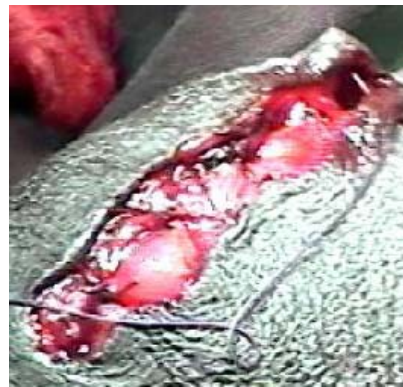

Photo 13 b

Photo 13 a, b. Closure of the scrotal wall in 2 layers: a) Inner scrotal wall; b) skin.

There is no need to put a drain in the scrotum before wound closure. Drains

do not stop bleeding and haematoma formation. They only show the surgeon whether bleeding is ongoing. Careful haemostasis during the procedure is what prevents bleeding. Also, drains increase the risk of infection.

14. Dressing and bandaging with crepe bandage.

- 14.1. Betadine* washing of the sutured surgical wound, twice;
- 14.2. Longitudinal compress;
- 14.3. 2 layers of compress across the scrotum;
- 14.4. Elastic band, 1st in direction of the longitudinal bandage, then circularly being careful to also include the apex again and to include the proximal aspect of the cord laterally as high as possible, and up to but not around the penis;
- 14.5. Tape the end of the elastic bandage to avoid subsequent unraveling (rather than using the clips supplied with the elastic bandage);
- 14.6. Apply a suspending tape from one side of abdomen via the apex of scrotum to other side of abdomen, with gentle degree of “lift” or tension in it.

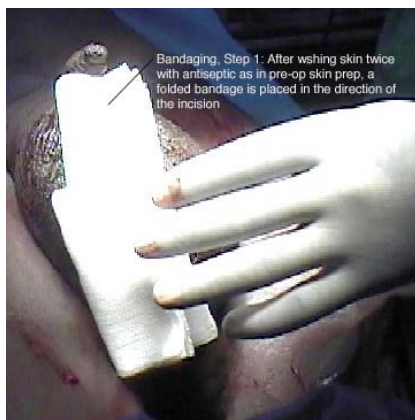

Photo 14 a

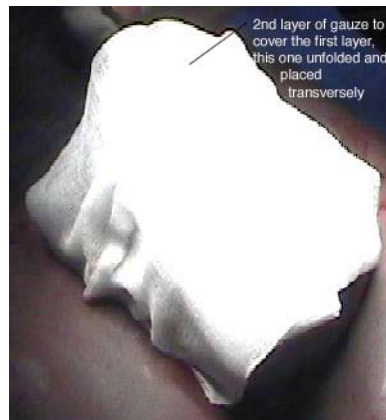

Photo 14 b

* The term “Betadine” is used here because it is utilized in many West African settings as a generic term for skin disinfectant used in pre-operative skin preparation. Any disinfectant suitable for coming in contact with subcutaneous tissues can be used. Also, please note: Some people react strongly against Betadine and other disinfectants containing iodine. If you see areas with changed skin when opening the bandage, it is important to refrain from using Betadine or any related substance for subsequent dressings and surgery.

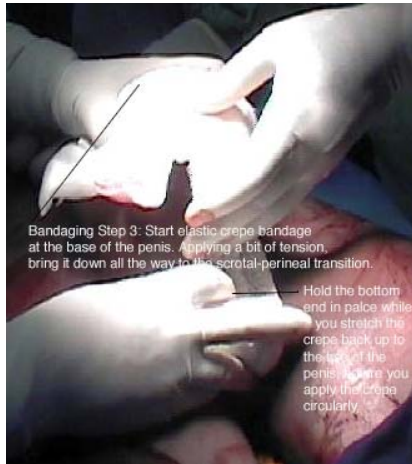

Photo 14 c

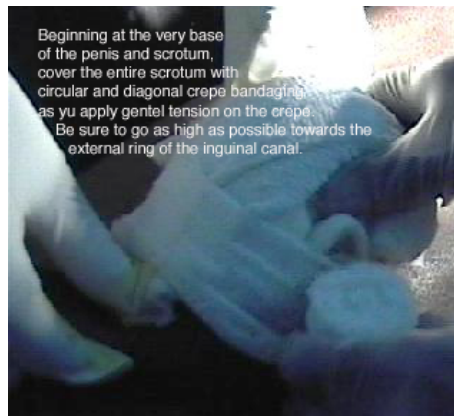


Photo 14 d

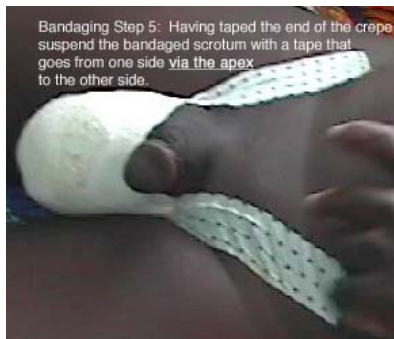

Photo 14 e

Photo 14 a – e. Steps in bandaging the scrotum

NOTE: Both surgeons should definitely stay for the bandaging process. It is very difficult to apply the bandage and get appropriate tension on the crepe bandage with just one pair of hands. One person must initially hold the end of the bandage at the base of the penis as the bandage is folded at the scrotal-perineal border, while the other unrolls the bandage and wraps it around the scrotum.

D. Post operative care

1. Routine Antibiotic Coverage (Please see footnote on page 13.)

Amoxicillin 500mg tab. 3x for 7 days. **and** metronidazole 400mg tab. 3x for 7 days (including ~~evening~~ the day before surgery, and the ~~day~~ morning of surgery)

IMPORTANT NOTE: The first dose of both antibiotics ~~should~~ must be given the previous ~~night~~ day, before surgery. Antibiotic treatment **WITH BOTH DRUGS** is then continued post operatively for 5 days, ~~beginning~~ including the morning of surgery and continuing when the patient is fully awake and comfortable on the afternoon of the surgery day. If there is an infection in spite of this treatment, it may require wound swabbing for culture and sensitivity analysis, and then local antiseptic/antibiotic in addition to ongoing systemic antibiotic treatment, or a change in systemic antibiotic.

2. Post-op. Analgesia (Please see cautionary note, just below!)

Diclofenac 50mg 3x for 5-7 days **or** ibuprofen 400mg 3x for 5-7 days.

NOTE: Caution is warranted concerning NSAIDs in patients who are hypertensive, diabetic, or old, because of the potential risk of acute renal insufficiency that may not be dose-dependent, and in patients with a history of dyspepsia.

Normal cautionary advice must of course be observed concerning all medications mentioned in this handbook.

3. MF+ Patients are treated with ivermectine and albendazole

Microfilaria-positive F+ P patients are treated with a single dose of albendazole (400 mg. p.o.) and ivermectin (Mectizan) 200 mg p.o. (In countries outside Africa; that are not endemic for onchocerciasis, DEC (diethylcarbamazine) 6 mg p.o. is given as a single dose instead of ivermectin, together with the albendazole.)

4. Hospital Admission

~~24—48 hours~~ One week postoperatively, and then discharge home if the wound is nicely closed and dry or the patient lives close enough to return for several any further bandage changes and other care that may be needed. s during the 1st week.

NOTE: Evaluations show that patients that can be followed up for bandage changes by a conscientious hospital nurse who is expert in surgical wound care do excellently, with essentially no complications following the procedure taught in these workshops. However even the best surgeons have seen 20% post operative infection rates in patients who returned to their villages for wound care after 2-3 days.

5. Change of dressing

The bandage should not be touched if it is clean the day after surgery!

Only if the bandage is soaked on the day after surgery is it to be removed and changed, ~~before the patient is sent home and seen back at the clinic on Day 3.~~

If the bandage is soaked with blood, one should consider giving 10 mg. Vitamin K i.m.

~~If the bandage is clean on the day after surgery and the patient otherwise ready, he can be discharged and must then be seen back at the clinic on Day 3 for inspection of the wound.~~

~~If the patient goes home after 48hrs, then the same principles apply. The wound should be inspected on Day 3 unless there is leakage before that, as seen on the outside of the bandage.~~

Sterile change of bandage on Day 3 and Day 5

It is important for a good result (avoiding secondary postoperative hemorrhage and infection) that the bandage change on both Day 3 and Day 5 be done using aseptic technique!

On Day 3, aseptic bandage change. Using sterile gloves, the surgeon or specially trained nurse carefully disinfects the surgical- wound and all of the scrotal area twice with Betadine or a similar disinfectant, using a new compress/gauze for disinfecting the area the second time, just as at surgery.

Use the same bandaging procedure as at surgery, with sterile compresses applied in the same way, followed by the elastic bandage applied in the same way, and finally a supporting tape, all applied as taught during the workshops and illustrated in Photo 14 a - e.

On Day 5, the patient should have return for a new aseptic bandage change. ~~,and then be seen again on Day 7.~~

On Day 7, aseptic technique should again be used. ~~not be necessary because~~ If the wound is ~~should be~~ dry and healing nicely. ~~In most other respects, the same bandaging technique can be used. For example, the same elastic~~ bandage can be used, but supportive taping is not ~~normally usually~~ needed because the patient's underwear will normally provide sufficient support from Day 7 onward.

If the skin is nicely healing and dry along the whole length of the incision, the patient can resume normal bathing after Day ~~5 or~~ 7 but should be sure to ~~not apply~~ avoid using any local, herbal, or other preparations ~~to on~~ the surgical wound.

On Day 14, if all is well, examination of the scrotum suffices.

Where absorbable sutures are used, the patient must be instructed not to remove them; suture knots will fall off after at most 6-8 weeks.

IMPORTANT NOTE: This close post-operative follow-up is essential because any post-operative infection can very quickly become seriously dangerous in this warm, moist part of the body, the more so in a tropical climate under conditions where modern levels of personal hygiene may not be achievable.

If there is any sign of local infection on Day 3, bandages should be changed ~~patients should be seen~~ daily until the incision heals nicely. Documentation of the state of the surgical wound at each post-operative examination is very important.

It is important to document all complications such as haemorrhage, haematoma, infection, recurrence etc.

6. Long term follow up

Long term follow-up for 3 - 5 years is ideal where possible, with a history taken on the patient's situation, with a physical examination, and if available also ultrasound.

After the wound heals and the patient is discharged from immediate post-operative follow-up at Day 14, follow-up monthly is suggested for two months, then at 6 months and one year, then only if they have any problem.

During these latter examinations, one is particularly interested in any sign of recurrence and in how the patient is doing.

NOTE: Document any changes in financial self-sufficiency or other quality-of-life indicators at follow-up as compared with before the operation. Annex 5 provides a format for recording desirable long-term follow-up data for monitoring and evaluating the project's outcomes.

The West African LF-Morbidity Project will attempt to follow up surgeons trained under the project, to collect data on patients operated on by these surgeons. The hope is to document the effectiveness of the protocol and the Project on a long-term basis, as well as to document the socio-economic benefits accruing to patients and their families. Participating surgeons who provide data on patients they have

operated on will be recognized in any resulting scientific publications.

E. External monitoring and Evaluation

The West Africa LF Morbidity Project [has done one evaluation and](#) intends ~~and hopes~~ to [again](#) have results of its surgical training efforts evaluated externally. It is envisioned that this will involve visits by an external surgeon to a randomly selected and significant proportion of patients operated on by those trained under the Project. The aim will be to ascertain surgery outcomes in terms of infections and other complications, as well as long-term beneficial and negative impact of operations. The main purpose of this effort will be to collect evidence for the benefit (or otherwise) of the project's activities in a scientifically reliable manner.

LITERATURE

Thambugala RL. Radical cure of filariciele of the tunica vaginalis; The technique of excision of the sac. 1971 *British Journal of Surgery*; Vol 58, No 7: 517-518.

Wright JE. Midline scrotal incision and simple dressing. 1966 *Medical Journal of Australia*; Vol. 2: 14-16.

Young HH. Radical cure of filariciele by excision of serous layer of the sac. 1940 *Surgery, Gynecology and Obstetrics*; 70: 807-812.

About pathogenesis and treatment of lymphoedema of genitalia and limbs

Dreyer G, Addiss D, Dreyer P, Noroes J. *Basic Lymphoedema Management; Treatment and Prevention of Problems Associated with Lymphatic Filariasis*. 2002. Hollis Publishing, USA; Available at: books@hollispublishing.com

In French:

Dreyer G, Addiss D, Dreyer P, Noroes J. *Guide pratique pour la prise en charge des cas de lymphoedema; Traitment et prevention des affections liées à la filariose lymphatique*. 2003. Hollis Publishing, USA; Available at: books@hollispublishing.com

About ultrasound diagnosis and lymphangectasia

Amaral F, Dreyer G, Figueredo-Silva J, Noroes J, Cavalcanti A, Samico SF, Santo A, Coutinho A. Live adult worms detected by ultrasonography in human bancroftian filariasis. *Am J Trop Med Hyg* 1994; 50:753-757.

Noroes J, Addiss D, Santos A, Medeiros Z, Coutinho A, Dreyer G. Ultrasonographic evidence of abnormal lymphatic vessels in young men with adult *Wuchereria bancrofti* infection in the scrotal area. *J Urology* 1996; 156:409-412.

About pathogenesis

Dreyer G, Noroes J, Figueredo-Silva J. Elimination of lymphatic filariasis as a public health problem. New insights into the natural history and pathology of bancroftian filariasis: implications for clinical management and filariasis control programs. *Trans Roy Soc Trop Med Hyg* 2000; 94:594-596.

Dreyer G, Noroes J, Figueredo-Silva J, Piessens WF. Pathogenesis of lymphatic disease in bancroftian filariasis: A clinical perspective. *Parasitology Today* 2000; 16:544-548.

About the twin approaches to LF elimination

Seim AR, Dreyer G, Addiss D. Controlling morbidity and interrupting transmission: twin pillars of lymphatic filariasis elimination. *Revista da Sociedade Brasileira de Medicina Tropical* 1999; 32:325-328.

ANNEX 1

PATHOGENESIS

The two most common urogenital manifestations of lymphatic filariasis develop in two ways, different for LF-hydrocele/filaricene on the one hand, and for lymphoedema and elephantiasis of the scrotum and penis on the other hand, although the same underlying pathology is behind both conditions.

Underlying pathology of the lymph vessels

In post-puberty males, the *W. bancrofti* parasite has a predilection for lymph vessels of the spermatic cord. In lymph vessels with a living nest of parasites, a gradual and continuous dilatation of the lymph vessel occurs as long as the adult worms are alive. The mechanism is as yet unknown but suspected to entail endothelial proliferation in the lymph vessels stimulated by substances secreted from the parasite. Dilatation stops when the adult worms die, leaving each lymph vessel irreversibly dilated as much as it was when the last adult worm died or was surgically removed.

LF-hydrocele / filaricene

Ordinary, non-filarial hydrocele contains fluid that is an ultra-filtrate accumulated in the tunica vaginalis. Such ultra-filtrate contains neither cells nor proteins to any significant degree.

LF-hydrocele/filaricene develops when lymphatic fluid from dilated scrotal lymphatics enters into the tunical space, presumably as a result of rupture of thin-walled lymphatic vessels. Unlike in congenital, non-filarial hydrocele, this is not a filtrate. It is lymph fluid, complete with lymphocytes, macrophages, and a wide variety of proteins. Lymph is damaging to tissue when present in large amounts outside the normal system of lymph capillaries and collecting vessels. Thus, testicular necrosis is seen in cases where large, longstanding filaricene has included leakage of the fluid to the testis itself. It is to avoid continuing leakage of lymph, with the risk of damage resulting to the testis and other scrotal tissues, that the LF-hydrocele sac is resected during the procedure taught by the West African LF Morbidity Project.

Lymphoedema and elephantiasis of the scrotum

The basic pathology behind disease in LF-lymphoedema and LF-hydrocele / filaricene is dilatation of the lymphatic vessels, lymphangectasia. Analogous to what occurs in veins when patients have varicose veins, the fine lymphatic valves that normally assure one-way flow cannot meet at the middle when the lymph vessel diameter increases too much; flow through the vessel becomes less efficient, and the area drained by that lymph vessel becomes less well protected against bacteria and other pathogens that daily cross the skin in small numbers, as a result of skin injuries (entry lesions), etc. The lymphatic insufficiency caused by LF allows larger numbers of bacteria to persist and even develop under the skin of the scrotum, a limb, or a female breast, leading to “acute attacks” with their characteristic inflammation.

Inflammation during acute attacks damages lymphatic capillaries, leading to lymphoedema and further lymphatic insufficiency, with an even greater tendency towards new acute attacks. A vicious cycle is thus established that progresses towards fibrosis, thickening of the cutaneous tissues, and development of elephantiasis.

That vicious spiral can be broken by careful daily skin hygiene with soap, water, thorough rinsing and careful drying, as well as protecting the skin against entry lesions. While the original lymph vessel dilatation is permanent, impressive clinical improvement and complete termination of disease progression is seen with proper, daily self-care measures undertaken by LF-lymphoedema patients.

ANNEX 2

LOCAL ANESTHESIA FOR LF-HYDROCELE / FILARICELE

Diazepam 10 mg. i.v. p.o. should be given to all patients just before about 2 hrs. prior to surgery.

In addition to calming the patient and alleviating the anxiety naturally associated with undergoing a surgical intervention, many patients experience a beneficial tendency towards a degree of amnesia for events experienced under a dose of that size. N.B. Pre-medication is important for a good result if local anesthesia is used.

Pethidine 50-100mg i.m., is given 5-15 minutes before surgery as a centrally acting analgesic and improves the effectiveness of the local anesthetic. An initial 50 mg. dose should be followed by an additional 25-50 mg. if the patient tolerates the first dose well and shows signs of needing additional analgesia during the procedure. Where Pethidine is not available, Tramadol 50 mg. can be injected as an antiinflammatory analgesic.

Lidocaine hydrochloride 2% with adrenaline 1/1000 dilution; Normally 5 40 ml. (Maximum Total Dose \leq 400 mg. Xylocain)

NOTE: In some countries Xylocain is available pre-mixed with adrenaline. Where this is not the case, for each 20 ml. of Xylocaine, placed in a small sterile bowl, one should add 1 ml of 1/1,000 concentration of adrenaline.

Adrenaline is an important component because it reduces bleeding.

Be sure to aspirate every time you insert the needle, before pushing on the plunger, to assure against injecting adrenaline intravascularly.

NOTE: As noted in the text itself, where available, bupivacaine (in a 1:1 dilution with normal saline or water ad inj.) gives a strong and longer lasting effect, and thus requires less drug for the same local anesthesia time. It may therefore also be less costly all told. However, in most of our settings, bupivacaine may not be available.

The following steps are employed when giving the lidocaine:

1. 10 5 ml of the lidocaine is injected into and in front of the spermatic cord on both sides (even for unilateral disease)(s), proximally, fairly close to the inguinal canal.
2. 10 ml is injected into the median raphae of the scrotum starting 2cm below the penis.
3. 20 ml is injected subcutaneously around the filaricele, spreading out from

the median raphae.

4. As and when necessary, the injections into the cord(s) are repeated depending on the patient's response. **Be sure to use an adequate amount (e.g. 5 or preferably 10 ml.) when topping up the local anaesthesia!!!**

ANNEX 3

RELEVANT ANATOMICAL HIGHLIGHTS

Please see illustration on the next page.

Arterial supply of the scrotal wall

Anterior scrotal arteries are branches of the internal pudendals and anastomose freely with the posterior scrotal arteries at the apex of the scrotum.

Posterior scrotal arteries are branches of the perineal artery (inferior perineal branch) given off at the base of the scrotum.

Collateral arterial supply to the testis

The artery to the vas and the cremasteric artery both supply collaterals to the testis. Therefore, in any cases where accidental damage is caused to the testicular artery, the testis can be left in place.

Venous drainage of the scrotal wall

Anterior scrotal veins accompany the anterior scrotal arteries, converge at the neck of the scrotum and join the external pudendal vein.

Posterior scrotal veins run with their respective arteries from the apex to the base of the scrotum and join the veins draining the posterior wall to become the perineal vein, which joins the internal pudendal vein in the pelvis.

Lymphatic drainage of the scrotal wall and contents, and the penis

A set of lymph vessels accompanies each set of arteries and veins, as usual. Superficial structures of the penis and scrotum are drained to a superficial group of inguinal nodes, while deep penile structures, including the penile urethra, drain both to those superficial nodes and to deep inguinal nodes. The testis drains directly to deep retroperitoneal, pelvic lumbar nodes.

It is this difference that explains why patients can have extreme lymphangectasia (dilatation) of scrotal cord lymphatics in LF-hydrocele / filaricele, while the scrotal skin is normal in most patients. Patients who have lymphoedema of scrotal skin also have similar pathology affecting the scrotal wall's drainage system. In those cases, damage to the scrotal wall's lymphatics has led to repeated "acute attacks" and cycles of damage to lymph capillaries, with fibrosis that can progress to elephantiasis, as in the legs. Such patients also have pathology of the separate testicular drainage system that has led to their LF-hydrocele / filaricele.

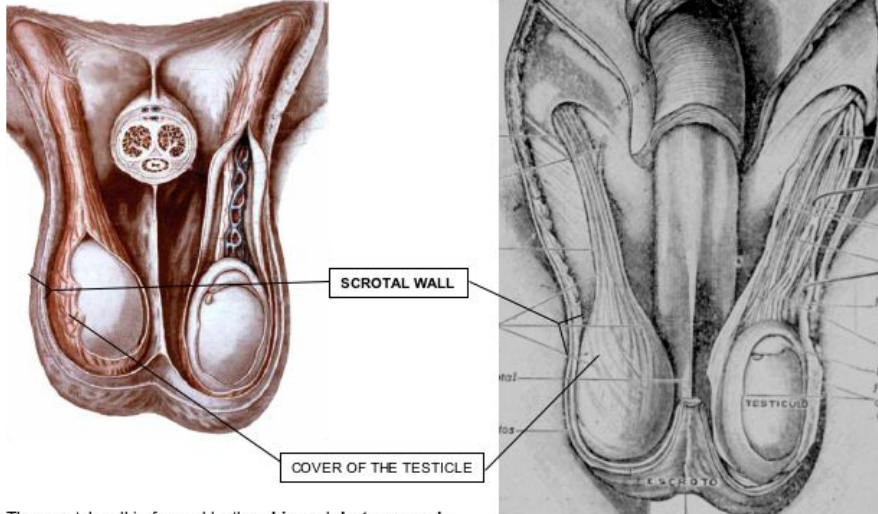
Innervation of the scrotum and its contents

Innervation of the scrotum and its contents is by the posterior cutaneous nerve of the thigh and the ilio-inguinal nerve (taking care of the dorsal and anterior aspects of the skin, respectively) and by the genital branch of the genito-femoral nerve (innervates contents of the spermatic cord and its contents including the testis and epididymis. The former nerve is on the ventral aspect of the spermatic cord. The latter nerve lies within the spermatic cord and follows the artery.

This pattern of innervation has very practical implications for filaricele surgery under local anesthesia: **Local anesthetic for the testis and epididymis must especially be placed in and in front of the spermatic cord at the start of surgery, and when topping-up may be needed.**

ANATOMICAL HIGHLIGHTS continued

When the hydrocele wall is thick, fibrosis usually affects the whole cover of the testicle, making it impossible to separate the parietal tunica vaginalis from the outer layers. Because the hydrocele wall always contains more than the parietal tunica vaginalis, it is generally more correct to call this the hydrocele sac rather than describing it as parietal tunica vaginalis.



1. The scrotal wall is formed by the **skin** and **dartos muscle**
2. Sequentially inward, the testicle cover consists of : **cremaster**
outer spermatic fascia
inner spermatic fascia
parietal tunica vaginalis
visceral tunica vaginalis
tunica albuginea

Illustration thanks to Prof. Joaquim Noroes

ANNEX 4

PATIENT CARE AND FOLLOW-UP FORM

Items to register for surgical care of LF filaricele patients[§]

Patient ID

- 1.Name:
2. Date of birth (age):
- 3.Marital status:
- 4.Occupation:
- 5.Address:

Characteristics of the filaricele

1. Duration of scrotal swelling:
2. Localisation:
3. Associated scrotal conditions:
4. Diameter:
 1. Ultrasound findings:
 2. Transillumination:
7. Estimated weight of the filaricele:

Other pathological conditions

1. Lymphoedema of limbs:

[§] Page 5 of this Manual is intended as a summary overview-page of patient-notes, presenting key pre-, per-, and post-operative information. Pages 5-7 can be photocopied and used as pre-operative patient charts. This form (pages 33-35) is intended for detailed documentation of treatment the patient receives, and the outcomes of treatment. It can also be photocopied and used as a checklist of things to remember and be aware of. Some items from pages 5-7 are therefore repeated here.

2. Hernia:

3. Laboratory tests: MF status: LF-antigen status:

Hgb: Urine: Others _____

Anaesthesia (for each category, write medication, dosage used, and time(s))

1. Pre-operative NSAID:

2. Local:

3. Spinal:

4. General:

Surgery

1. Date, start-time, stop-time, duration:

2.a. Surgical procedure(s) carried out:

2.b. Orchiectomy ?

(In situations where a testis was necrotic and in cases that turned out to be tumor testis, i.e. non-LF-related tumor)

2.c. Herniorrhaphy ?

(In situations where hernia turned out to be the diagnosis or co-existed with a filariciele)

3. Nature of filariciele fluid:

8. Volume of fluid:

Medication

1. Antibiotics:

2. Analgesics:

3. Antifilarial TX:

5. Other medications:

Including, if given, any tetanus toxoid, infusions, Vitamin K, blood transfusion, iron supplementation (if the patient is anaemic), etc.

Complications

Immediate (Day 0-5; specify when, and describe)

1. Haemorrhage:
2. Haematoma
3. Infection
4. Other

Late (Day 6 and beyond; specify when, and describe)

1. Infection (including any scrotal abscess):
2. Haematoma:
 1. Haemorrhage (secondary):
 2. Wound breakdown:
 3. Necrotic testis:
 4. Fournier's gangrene:
 5. Lymphoedema/lymphscrotum:
 6. Recurrence:

Duration of hospitalization and follow-up

1. Duration of hospitalization:
2. Period of follow up:
3. Period before stitch removal: (In cases where resorbable sutures were not used)

General comments

Date(s), Surgeon's name and Signature

ANNEX 5 - Surgery Outcomes Data Registration Form (Draft) (1st of 2 pages)

Nr. _____ /¹

1. Name of the Patient (family name, given name):
2. Date of birth ____/____/____/ Age ____ years
3. Village/Town of residence:
4. District : _____ Region : _____
5. Duration of the disease : _____ years
6. Diagnosis - initial :
7. Ultrasound findings (if done)
8. Date of hospitalisation : ____/____/____/
9. Operative findings and technique used :
10. Operation outcomes :
11. Diagnosis - final :
12. Date of departure from hospital : ____/____/____/
13. Duration of hospitalisation _____
14. Direct Cost of the actual surgery² : /_____/
15. Post operative follow-up findings:
- Week 1 :
- Week 2 :
- Month 1 :
- Month 6 :
- Year 1 :
- Year (____):

Please ask the patient the questions printed on the next page as part of the follow-up assessment.

¹ Number of the patient next to the initials for the hospital

² Include the cost of medications, the surgery itself, and the hospitalisation

ANNEX 5 - Surgery Outcomes Data Registration Form (2nd of 2 pages)

Four Socio-economic topics to ask the patient about

Patient name and residence (or number as noted at the top of this Annex): _____

Assessment time point:

__ 6 months post-op __ 12 months post-op __ 18 months post-op __ 24 months post-op __ other (please specify) _____

Request to the patient:

I am going to ask you some questions.

Please indicate which statement best describes your own situation today.

16. General satisfaction with the surgical procedure: _____
1. I have no problems after the operation, and am glad that I had the surgery done
 2. I have some problems after the operation, but I am glad that I had the surgery done
 3. I do not know if I am glad that I had the surgery done or not
 4. I wish I had not had the surgery done (Please explain: _____)
17. Change in ability to work because of the surgery: _____
1. My ability to work is much better after the surgery than it was before
 2. My ability to work is a little better after the surgery than before, but not much
 3. My ability to work after the surgery is the same as it was before
 4. My ability to work is worse than it was before the surgery (Please explain: _____)
18. Change in economic situation after the surgery: _____
1. The surgery made my economic situation much better
 2. The surgery made my economic situation better than before, but not much
 3. The surgery made no difference to my economic situation
 4. The surgery made my economic situation worse (Please explain: _____)
19. Change in Family life after the surgery: _____
1. The surgery made my family life very much better than it was before
 2. The surgery made my family life better than before, but not much
 3. The surgery made no difference to my family life
 4. The surgery made my family life worse. (Please explain: _____)

NOTE: It is suggested that national LF elimination programmes and interested surgeons do more thorough prospective assessments of the socio-economic impact of LF-hydrocele disease and the impact of its repair. The Euro-Qol scale and WHO's WHODAS scale seem among the well suited tools that can be useful when doing formal prospective studies. The LF Monitoring & Evaluation support group in Atlanta (accessible through CDC (US Centers for Disease Control and Prevention) or The Task Force for Child Survival, both in Atlanta, USA) may be able to help in designing rigorous, prospective socio-economic impact studies. Such expertise may also be accessible through the African LF Support Centre at the Nogouchi Memorial Institute in Accra, Ghana.

ANNEX 6

RECIPIE FOR POTASSIUM PERMANGANATE SOLUTION

Add 100mg of potassium permanganate crystals to 100ml. of water (equals 1 gram of potassium permanganate crystals to 1 litre of water for large amounts).

Store the solution in an amber coloured bottle away from light.

The freshly prepared solution should be used within seven days.

This potassium permanganate solution is useful for skin disinfection and cleansing for all kinds of skin ulcers, bacterial and fungal skin infections, and for applying to gauze or clean strips of white cotton cloth that can be soaked and inserted, even as wicks, into skin-folds or between toes, when treating advanced lymphoedema caused by LF (or other conditions).

ANNEX 7

EQUIPMENT LIST

Kit for Filariciele Surgery

Proposed by
Dr. Sunny Mante
 as revised June April 2007 5

Disposables	Number pr. patient
Gowns	3 (1 for each scrubbed person)
Caps	3 (Depends on nr. in op. room)
Small drapes	2
Big drapes	1
Trolley towel	2
Non permeable/plastic apron	3
Abdominal towels	2
10 ml syringe	4
24G needles	4
Surgical blades (e.g. size 10 or 15)	1
Masks	3 (Depends on nr. in op. room)
Gauze (e.g. 10 x 10 cm compresses; sometimes 30cm. x 30 cm <u>compresses</u>)	50 compresses (30 compresses at surgery + 20 for post op. skin disinfection and dressings, Days 3, 5 and 7)
Sutures: Vicryl/Maxon/Dexon **4remove the four*** <u>3-0</u> — If Chromic catgut, — not thinner than 3-0 (3-0 or 2-0 can be used where <u>3-0 4-0</u> is un available)	5
Gloves (Note: Size is individual, usually 7 1/2 - 8)	6 pairs (double-set for each person scrubbed; 2 surgeons, 1 nurse)
Crepe bandage	24-5 <u>24-5</u> rolls (1 at surgery; 1 at bandage change Days <u>3, 5, 7;</u> <u>plus any additional</u>) patient washes the first and brings it to Day 5 & 7 bandage changes)
Plaster, 6 inch width (Note: Sticky tape for bandaging, not plaster as in "plaster cast")	2-3 rolls/week, depending on how many cases

Infusion set	1 - In readiness
Surgical hand wash brushes	3 (1/person scrubbed-in)

<u>Medications & solutions</u>	<u>Amount/patient</u>
Diazepam 10mg <u>injection</u> tablet	1 <u>ampoule</u> tab-
Pethidine ad inj. 100mg	1 ampoule
2% lidocaine <u>with adrenaline</u> injection	2 x 5 20 ml. (<u>for unilateral cases</u>)
Amoxycillin capsules 500mg	3x /day for 7days
Metronidazole Capsules 400mg	3x /day for 7 days
Diclofenac tablets 50mg	3 x /day for 5days
Vitamin K injection 10mg <small>For the rare-patients <u>with found bleeding first day post-operatively, a bleeding tendency who would not stop bleeding until you give them vitamin K-</u></small>	3 ampoules (In readiness only. Not routine.)
Povidone iodine solution	250 ml. (<u>including for-bandage-</u> changes)
Dextrose saline infusion	500 ml. In readiness
Normal/saline infusion	500 ml. In readiness

<u>Non disposables</u>	<u>Number</u>
Surgical blade handle	1
Small artery forceps	5
Big artery forceps	5
Small needle holder	1
Big needle holder	1
Mayo scissors	2
Metzemaum scissors	1
Allis clamps	2
Towel clips	4
Gallipot / Bowl for sponges	1
Kidney dishes	2

Dissecting forceps - toothed	1
Dissecting forceps - non toothed	1
Sponge holding forceps	1

Photos: G. Dreyer – Photos 1, 4.
S. D. Mante - Pages 2 and 3; and photos nr. 2, 3, 5, 6, 8-11, 13, 14.
J. Noroes – Anatomy illustration, p. 32.
A. R. Seim – Photos 7, 12.

Acknowledgements

The *West African LF Disability Project*, for which this handbook is produced, was supported in its initial pilot year by The Bill and Melinda Gates Foundation, Catholic Medical Mission Board (CMMB), Interchurch Medical Assistance (I.M.A.), and HDI (Health & Development International). The government of Norway ~~has is~~ provided ing funding for the Project in 2005 ~~–2007~~ through NORAD, and Johnson & Johnson has kindly provided support for medical and surgical supplies used in the training workshops, ~~also~~ beginning in 2005.

Professor Gerusa Dreyer and Professor Joaquim Noroes have contributed massively to this handbook in so many ways, and we extend our profound appreciation to them both. Dr. Yao Sodahlon kindly provided the basis for the first page of Annex 5, while the LF Monitoring and Evaluation Group in Atlanta USA provided generous input that led the authors to formulate the questions on the second page of Annex 5. We gratefully acknowledge the patients who allowed themselves to be photographed, so their experiences can assist in the training of surgeons throughout West Africa. And we similarly acknowledge the ~~Togolese~~ surgeons who have provided valuable inputs through the questions they asked, their discussion and comments, during the training workshops, the 2006 evaluations in Burkina Faso, Ghana, and Togo, and the June 2007 workshop in Senegal. ~~in Kara, Togo, in January 2005.~~ Also, we extend our warmest thanks to the many others who in many multiple ways large and small have made this handbook and the entire West African LF Morbidity Project possible.

Production of this handbook's first edition (2005) in English was supported by funding from The Bill and Melinda Gates Foundation, and HDI. The handbook was is being translated into French in 2006 with support from Johnson & Johnson, and will be available in French as soon as possible.

Printed in Norway by HDI, ~~– November 2005.~~

NOTES

